



Received for publication: October 3, 2018  
Accepted: December 6, 2018

## Case report

# Chest wall osteosynthesis after trauma using titanium plates: case report

Felix Dobritoiu<sup>1</sup>, Mihai Dumitrescu<sup>2\*</sup>, Daniela Dobritoiu<sup>1</sup>

<sup>1</sup>Ponderas Academic Hospital, Department of Thoracic Surgery, Bucharest, Romania

<sup>2</sup>Marius Nasta Institute of Pneumology, Department of Thoracic Surgery, Bucharest, Romania

### Abstract

*Introduction.* Flail chest can become life-threatening when accompanied by other complications of thoracic trauma. Current hospital flail chest management includes mechanical ventilation and pain control. Although mechanical ventilation management is constantly improving, prolonged intubation and intensive care lead to increased morbidity. Surgical fixation is gaining more ground against non-operative care and authors have reported better outcome and fewer complications in restricted retrospective studies, but a consensus still has to be reached regarding the guidelines for surgical fixation. In this article, we wish to present our perspective on the surgical fixation of flail chest. *Materials and Method.* A 39-year-old patient, known with chest trauma after a car accident for which he had undergone surgical treatment at another department, was admitted to our unit for chest instability and chronic pain. During the clinical examination of the left hemithorax, we noticed chest wall instability at the posterior arches of the 8th, 9th and 10th left ribs. CT scans of the thorax showed approximation of the ribs on the anterior fracture line and multiple displaced rib fractures, without callus formation, on the posterior fracture line. *Results.* The 5th to 10th left ribs were cleared of fibrotic tissue, re-approximated and repositioned using matrix RIB titanium plates and screws. After surgery, the patient was kept in the intensive care unit for two days and was discharged after another seven days. Postoperative pain was managed with opioid therapy. *Conclusions.* The debate regarding the operative management vs. the non-operative management of flail chest is ongoing given the relatively small number of patients included in the existing randomized-controlled trials. Osteosynthesis with plates and screws is easy to manage and we recommend the use of operative treatment of flail chest in patients who can withstand thoracic procedures.

### Keywords

: flail chest, fixation, osteosynthesis, titanium plates

### Highlights

- ✓ The operative treatment of flail chest is recommended in patients who can withstand thoracic procedures under one lung ventilation anesthesia.
- ✓ The non-operative management in patients with flail chest can lead to recurrent hemopneumothorax and chronic pain caused by the free movement of rib fragments.

**To cite this article:** Dobritoiu F, Dumitrescu M, Dobritoiu D. Chest wall osteosynthesis after trauma using titanium plates: case report. *J Clin Invest Surg.* 2019; 4(1): 53-57. DOI: 10.25083/2559.5555/4.1/53.57

## Introduction

Flail chest is defined as three or more fractured ribs, presenting at least two fracture lines each, which lead to chest wall instability during respiration. Flail chest determines up to 15% of all chest wall injuries and can become life-threatening following severe chest trauma when accompanied by other complications of thoracic trauma such as pneumothorax, hemothorax and lung contusions (1- 4).

Modern solutions for the treatment of flail chest were introduced as early as the 1950s, with internal pneumatic stabilization gaining popularity fast. Still, this method proved unnecessary in patients without respiratory distress and in 1970, Trinkle et al published evidence advocating pain control and pulmonary toilet in stable patients (5).

Mechanical ventilation is nowadays reserved for patients with persistent respiratory distress or for patients with complications due to narcotic use.

Although mechanical ventilation management is constantly improving, prolonged intubation and intensive care stay lead to tracheal injuries, pneumonia and decubitus ulcers which increase morbidity and prolong hospital stay (3-4).

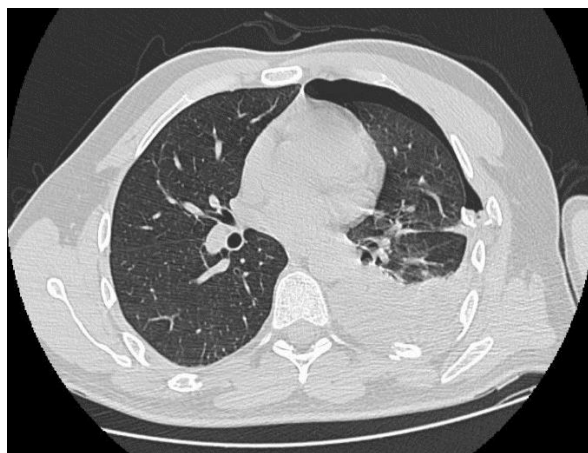
Two recent studies have shown that continuous positive airway pressure can decrease mortality by reducing incidence of nosocomial pneumonia in the intensive care unit, but failed to show reduced length of stay in the intensive care unit (6-7).

Surgical treatment is not routinely used despite the increasing number of reports showing improved long-term outcome, when compared to mechanical ventilation only, and reduced costs of hospitalization for patients with flail chest. Surgical treatment mainly consists of hardware fixation with plates and screws (8-10).

In this case report we intend to present our approach to surgical fixation of flail chest by using titanium plates and screws.

## Materials and Methods

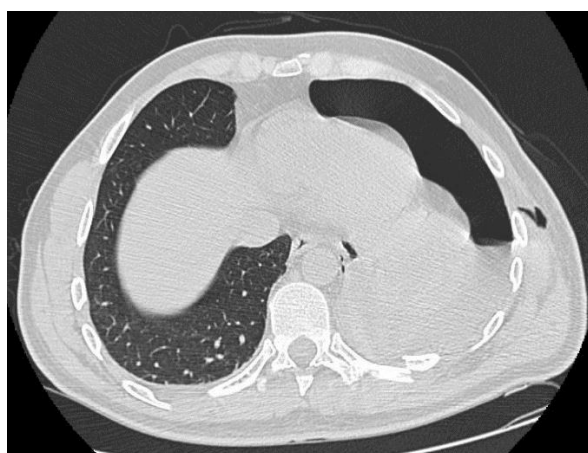We present the case of a 39-year-old patient, involved in a car crash (rally car driver), who was admitted to the emergency room of a county hospital in critical state, with lacerated spleen, left hemopneumothorax, manubrium fracture and 23 rib fractures (rib 1 on the right side and ribs 1 - 12 on the left side)- Figure 1.



**Figure 1.** CT scan of the thorax showing a rib fragment penetrating the lung and causing pneumothorax and hemothorax

The patient was transferred to the operating room to undergo splenectomy and chest drainage. Prior to splenectomy, a chest tube was inserted into the left pleural cavity for drainage of blood and removal of air. He was discharged one week later in a good clinical state and with documented left lung expansion.

Ten days later, the patient was readmitted to the same county hospital for recurrent left hemopneumothorax; Figure 2.



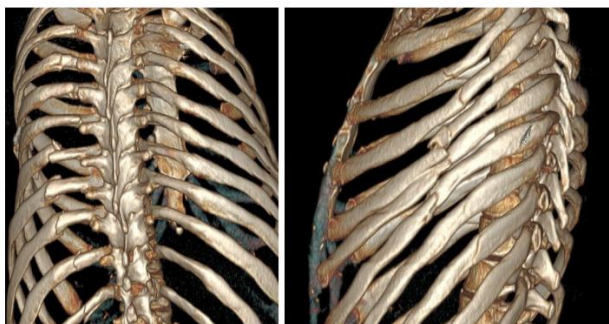
**Figure 2.** CT scan of the thorax, 17 days after the accident, showing left hydropneumothorax

Exploratory left lateral thoracotomy performed through the fifth intercostal space led to the discovery of four pulmonary lesions, with air leakage, and hemorrhage from the fracture lines of ribs 4 to 7. The pulmonary lesions were sutured and the ribs 4 to 7 were re-approximated with sutures on the lateral line of the fracture after hemostasis. The patient was discharged ten days later in a good clinical state.

On the 33rd day after the trauma, the patient is admitted to “Ponderas” Academic Hospital with excruciating pain, dyspnea and severe limitation in movement due to pain.

During the clinical examination of the left hemithorax, we noticed chest wall instability at the posterior arches of the 8th, 9th and 10th left ribs.

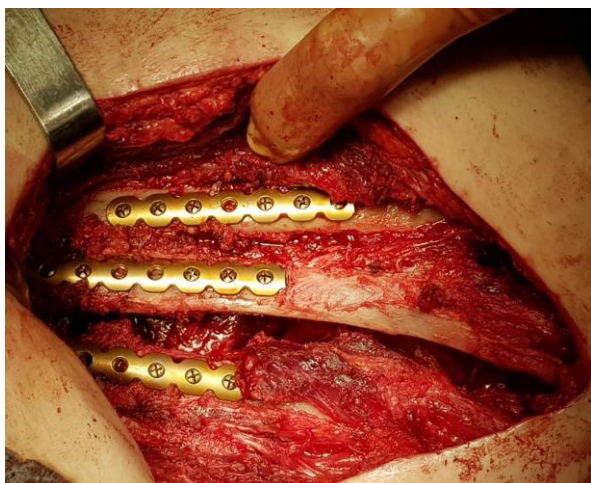
The CT scans of the thorax showed approximation of the ribs on the anterior fracture line and multiple displaced rib fractures, without callus formation, on the posterior fracture line; Figure 3.



**Figure 3.** 3D reconstruction of the thorax after CT scan, 34 days after the accident, showing angled and displaced 8th, 9th and 10th left ribs.

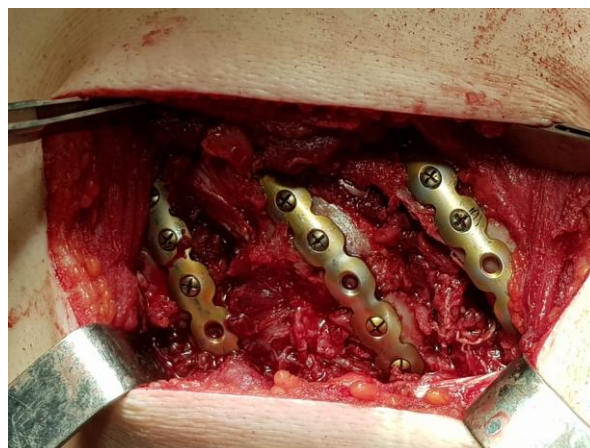
On the 36th day after the accident, the patient is taken to the operating room for the surgical treatment of the 4th to 7th ribs on the lateral fracture line and 8th to 10th ribs on the posterior line.

On the lateral fracture line, the redo surgery proved challenging due to extreme fibrosis and inflammation which led to significant hemorrhage. The 5th, 6th and 7th ribs were cleared of fibrotic tissue, re-approximated and repositioned using three matrix RIB titanium plates with eighteen 10mm-locking screws; Figure 4.



**Figure 4.** Lateral fracture line of the 8th, 9th and 10th left ribs with matrix RIB plates and locking screws.

A separate incision was made for the posterior fracture line of the 8th to 10th left ribs. The three ribs were completely fractured and displaced 1-1.5 cm into the pleural cavity. The ribs were repositioned using 3 matrix RIB plates with seventeen 10mm-locking screws; Figure 5.



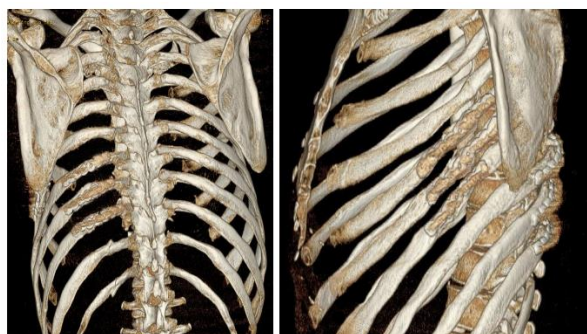
**Figure 5.** Posterior fracture line of the 8th, 9th and 10th left ribs with matrix RIB plates and locking screws.

## Results

After surgery, the patient was kept in the intensive care unit for two days and was discharged after another seven days. In order to manage the intercostal pain, the treatment of choice was opioid therapy with Fentanyl transdermal patches and Sevredol pills.

Opioids were started on day four with 50mcg/h for twelve days. Afterwards, the opioid dose was gradually reduced to 25mcg/h for the next four days, lowered to 20mcg/h for another two days and to 10mcg/h for the last day. After that, pain was easily managed with usual antalgic therapy.

One month after surgery, the patient has no signs of chest wall instability and he is able to swim and run painfree, Figure 6.



**Figure 6.** 3D reconstruction of the thorax after CT scan, performed 90 days after surgery, with osteosynthetic plates visible on the 5th, 6th, 7th, 8th, 9th and 10th left ribs



## Discussions

The debate regarding the operative management vs. the non-operative management of flail chest is ongoing given the relatively small number of patients included in the existing randomized-controlled trials (3, 4, 11).

In their series of 42 patients with multiple rib and sternum fractures, who underwent operative fixation using titanium plates and screws, Richardson et al concluded that the movement of free bone fragments not only causes severe pain and respiratory distress, but also results in nonunion (8).

Althausen et al conducted a retrospective study to compare the results of the surgical stabilization to non-operative care in patients with flail chest, at a II level trauma center, and presented the results of the 22 patients treated with locked plates and 28 patients with non-operative care. Operated patients had shorter intensive care unit stay, reduced ventilator assistance, fewer complications such as tracheal stenosis or infections and decreased oxygen requirements. The study also demonstrated the reliability of the locked plates with no hardware failure recorded (10).

Schuermans et al reported in their systematic review of the literature that pneumonia rate, the duration of mechanical ventilation and the length of hospitalization were lower for patients with operative management, though there was no significant difference in mortality between the operative and non-operative groups (12).

Similar results were also reported by Doben et al in their study regarding the treatment of flail chest deformity by use of surgical rib fixation conducted in a I level trauma center. The surgical group had reduced ventilator days (4.5 days) as compared to the non-operative group (16 days) and decreased morbidity (13).

In their meta-analysis, Coughlin et al concluded that the stabilization of the ribs in flail chest should be performed as soon as possible because the dissection and mobilization of the ribs is easier, access to the pleural cavity is better and rib stabilization offers significant clinical benefits (14).

The Cochrane database systematic review on the surgical versus non-surgical treatment of flail chest conducted by Cataneo et al included 123 patients, from three studies, with flail chest injuries. The studies included did not find any clear evidence of difference in mortality between the treatment groups, but it seems that the analysis of these studies was underpowered to detect such differences between the groups. Although the studies included in the analysis reported a better outcome of the

surgical treatment, especially in reducing intensive care unit stay and morbidity, the authors of the review consider that further studies are required to confirm these results and establish differences in mortality (15).

Another meta-analysis for surgical fixation vs non-operative management of flail chest, conducted by Slobogean et al, which included data from Medline, Cochrane and Embase databases, analyzed the results of 753 patients enrolled in 11 studies. In the analyzed patients, surgical fixation led to better outcome with fewer ventilation days and fewer odds of developing pneumonia. The results suggest flail chest patients may benefit from surgical fixation; however, the authors of the meta-analysis consider that additional prospective randomized trials are necessary since most of the analyzed studies were restricted retrospective studies (16).

## Conclusions

The existing evidence present in the literature supports surgical fixation as a treatment of choice in patients with flail chest injuries who can tolerate lung ventilation; however, in the absence of large prospective randomized studies which can clearly demonstrate reduced mortality and morbidity in favor of surgical fixation, a consensus cannot be reached between fellow practitioners. Leaving aside the guidelines and inclusion criteria for surgical fixation, there is of course the debate on which type of fixation hardware offers the best stability and, at the same time, the minimum chance for infection and nonunion in both ribs and sternum.

In the case of our flail chest patients, non-operative management led to recurrent hemopneumothorax and chronic pain caused by the free movement of rib fragments which required a 27-day hospital stay and three thoracic procedures, two of which under general anesthesia.

On our unit, we support operative treatment of flail chest in patients without morbidities who can withstand thoracic procedures under one lung ventilation anesthesia.

The hardware of choice for us was the “matrix RIB plates and locking screws” kit made up of titanium, which was easy to work with. The removal of the hardware is not mandatory, although it is impossible to assess the risk of plate migration during future chest trauma.

## Conflict of interest disclosure

There are no known conflicts of interest in the publication of this article. The manuscript was read and approved by all authors.

## Compliance with ethical standards

Any aspect of the work covered in this manuscript has been conducted with the ethical approval of all relevant bodies and that such approvals are acknowledged within the manuscript.

## References

1. Ciraulo DL, Elliott D, Mitchell KA, Rodriguez A. Flail chest as a marker for significant injuries. *J Am Coll Surg*. 1994; 178(5): 466–470. PMID: 8167883
2. Kaufmann CR. Trauma, sixth edition. 6. United States: The McGraw-Hill Companies; 2008.
3. Tanaka H, Yukioka T, Yamaguti Y, Shimizu S, Goto H, Matsuda H, Shimazaki S. Surgical stabilization of internal pneumatic stabilization? A prospective randomized study of management of severe flail chest patients. *J Trauma*. 2002; 52(4): 727–732. PMID: 11956391
4. Marasco SF, Davies AR, Cooper J, Varma D, Bennett V, Nevill R, Lee G, Bailey M, Fitzgerald M. Prospective randomized controlled trial of operative rib fixation in traumatic flail chest. *J Am Coll Surg*. 2013; 216(5): 924–932. DOI: 10.1016/j.jamcollsurg.2012.12.024
5. Trinkle JK, Richardson JD, Franz JL, et al. Management of flail chest without mechanical ventilation. *Ann Thorac Surg*. 1975; 19(4): 355–63. PMID: 235908
6. Gunduz M, Unlugenc H, Ozalevli M, Inanoglu K, Akman H. A comparative study of continuous positive airway pressure (CPAP) and intermittent positive pressure ventilation (IPPV) in patients with flail chest. *Emerg Med J*. 2005; 22(5): 325–9. PMID: 15843697
7. Tanaka H, Tajimi K, Endoh Y, Kobayashi K. Pneumatic stabilization for flail chest injury: an 11-year study. *Surg Today*. 2001; 31(1): 12–7. PMID: 11213036, DOI: 10.1007/s005950170213
8. Richardson JD, Franklin GA, Heffley S, Seligson D. Operative fixation of chest wall fractures: an underused procedure? *Am Surg*. 2007; 73(6): 591–6; discussion 596–7. PMID: 17658097
9. Pettiford BL, Luketich JD, Landreneau RJ. The management of flail chest. *Thorac Surg Clin*. 2007; 17(1): 25–33. PMID: 17650694, DOI: 10.1016/j.thorsurg.2007.02.005
10. Althausen PL, Shannon S, Watts C, Thomas K, Bain MA, Coll D, et al. Early surgical stabilization of flail chest with locked plate fixation. *J Orthop Trauma*. 2011; 25(11): 641–7. DOI: 10.1097/BOT.0b013e318234d479.
11. Granetzny A, Abd El-Aal M, Emam E, Shalaby A, Boseila A. Surgical versus conservative treatment of flail chest. Evaluation of the pulmonary status. *Interact Cardiovasc Thorac Surg*. 2005; 4(6): 583–587. DOI: 10.1510/icvts.2005.111807.
12. Schuurmans J, Goslings JC, Schepers T. operative management versus non-operative management of rib fractures in flail chest injuries: a systematic review. *Eur J Trauma Emerg Surg*. 2017; 43(2): 163–168. DOI: 10.1007/s00068-016-0721-2.
13. Doben AR, Eriksson EA, Denlinger CE, Leon SM, Couillard DJ, Fakhry SM, et al. Surgical rib fixation for flail chest deformity improves liberation from mechanical ventilation. *J Crit Care*. 2014; 29(1): 139–43. PMID: 24075300, DOI: 10.1016/j.jcrc.2013.08.003
14. Coughlin TA, Ng JW, Rollins KE, Forward DP, Ollivere BJ. Management of rib fractures in traumatic flail chest: a meta-analysis of randomised controlled trials. *Bone Joint J*. 2016; 98-B(8): 1119–25. DOI: 10.1302/0301-620X.98B8.37282.
15. Cataneo AJ, Cataneo DC, de Oliveira FH, Arruda KA, El Dib R, de Oliveira Carvalho PE. Surgical versus nonsurgical interventions for flail chest. *Cochrane Database Syst Rev*. 2015 Jul 29; (7): CD009919. DOI: 10.1002/14651858.CD009919.pub2.
16. Slobogean GP, MacPherson CA, Sun T, Pelletier ME, Hameed SM. Surgical fixation vs nonoperative management of flail chest: a meta-analysis. *J Am Coll Surg*. 2013; 216(2): 302–11.e1 PMID: 23219148, DOI: 10.1016/j.jamcollsurg.2012.10.010